

〈CASE REPORT〉**Successful treatment of pediatric endocarditis and pericarditis due to MRSA with linezolid**

TAKASHI MIYAMOTO*, TAKAHIRO TOMOYASU and KAGAMI MIYAJI

The Departments of Cardiothoracic Surgery, Kitasato University School of
Medicine, Kanagawa, Japan

(Received for publication December 6, 2010)

The linezolid treatment for methicillin-resistant *Staphylococcus aureus* (MRSA) infection was sporadically reported in children. Here we describe a case of a 6 month-old patient underwent mediastinal drainage and artificial conduit removal caused by MRSA infection. After that, linezolid treatment was started and bacteremia was resolved after 14 days of treatment. At discharge, he was no febrile, his blood culture were sterile. We report a case of a patient with MRSA endocarditis treatment with linezolid.

Introduction

Recent findings have focused on the possible role of linezolid as a suitable candidate for the treatment of methicillin-resistant *Staphylococcus aureus* (MRSA). MRSA infections are emerged as the most common cause of postoperative complications. Some investigations suggest that MRSA infections are associated with prolonged hospitalizations increased mortality, mobility and costs. Therapeutic options for patients with MRSA infections are limited. Vancomycin has been the standard treatment until recently. However, the potential of vancomycin is ineffective and the development of vancomycin resistant-enterococci (VRE) proliferate has been very rapid with continued use of vancomycin. Linezolid, the first member oxazolidinone class of antimicrobial agent, applied for the treatment of infections caused by MRSA in Japan. We have a case of patient with MRSA endocarditis and pericarditis who was successfully treated with linezolid after glycopeptides treatment failed.

Case

A six months old boy patient underwent mediastinal drainage and artificial conduit [polytetrafluoroethylene (PTFE) graft] removal caused by MRSA infection. A multiple ventricular septal defect (VSD), coarctation with hypoplastic left ventricle was diagnosed in a 3-month-old boy weigh-

ing 5.3 kg. This patient then follows a single ventricle pathway, making them candidates for future Fontan palliation. First surgical procedure, simultaneous repair of coarctation of the aorta and pulmonary artery banding, was performed through a left thoracotomy at 4 month-old. Second operation, Damus-Kaye-Stansel (DKS) anastomosis and right ventricle–pulmonary artery conduit (RV–PA conduit) interposition with a 5 mm polytetrafluorethylene (PTFE) graft, was done at 5 month-old. The postoperative course was stable condition with respect to surgical mortality, neurologic events and infection. At discharge, his blood cultures were sterile and a transesophageal echocardiogram (TEE) showed no evidence of endocarditis.

One month later the patient returned to our department because of intermittent high fever and anemic conditions. High-grade bacteremia with MRSA was diagnosed because his blood cultures sets grew a MRSA strains. An antimicrobial regimen of vancomycin was initiated. The patient was still bacteremic after several days of treatment and his infectious factors, CRP and WBC, were increased. Though both chest X-ray and echocardiography were negative findings, high-grade bacteremia with MRSA was diagnosed from the blood culture and the computerized tomography (CT) showed a 5 mm abscess at the anastomosis between the PTFE graft and the right ventricle. Therefore, we decide to remove and replacement the PTFE graft with surgical intervention because the inner and outer abscess (Figure 1). The medicine sensitivity inspection of MRSA the fully automatic which conforms to the microdirution method which Clinical and Laboratory Standards Institute (CLSI) recommends recently in system MicroScanWalkAway-96 (DADE Behring) measured the Minimum Inhibitory Concentration (MIC) making use of the Pos Combo41J panel (DADE Behring). Furthermore, it measured the MIC of vancomycin (VCM) with the Pos Combo41J panel,

Fig. 1. The intraoperative picture show the abscess around the RV-PA conduit.

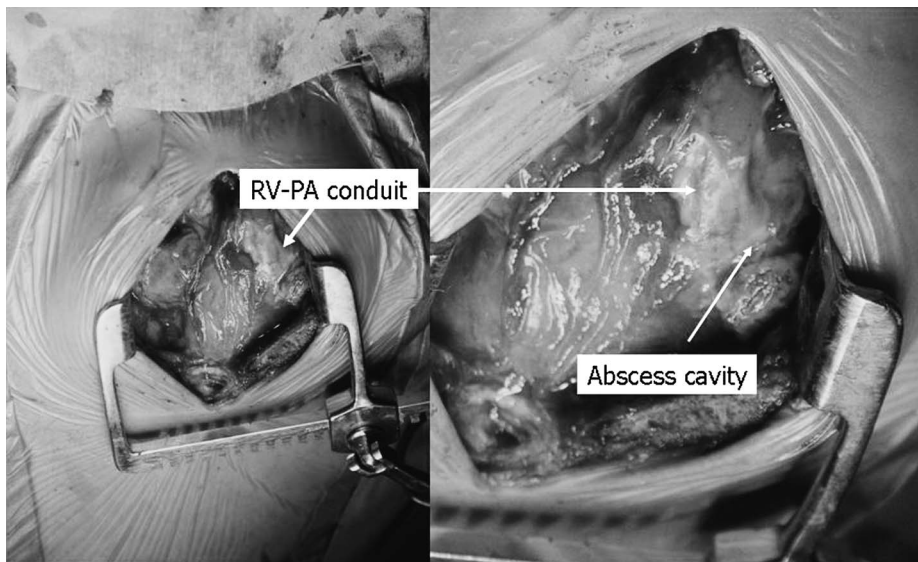
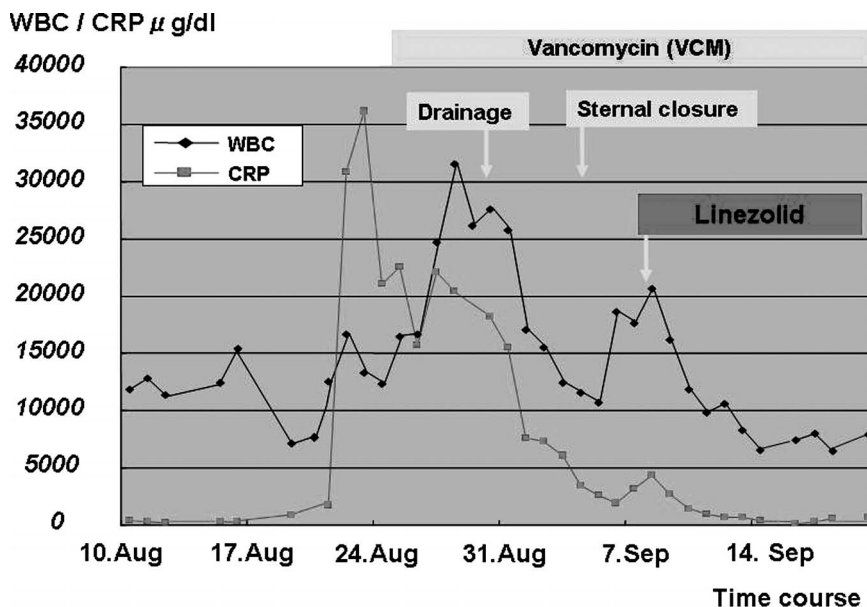


Fig. 2. Perioperative values of C-reactive protein and WBC counts.



it measured the MIC of linezolid (LZD), making use of nutrient medium Mueller Hinton nutrient medium (Becton Dickinson) for medicine sensitivity test and Etest “[asuka]”. As for the result, as for VCM MIC < as for the MIC of 2.0 $\mu\text{g}/\text{mL}$ and LZD < 1.0 $\mu\text{g}/\text{mL}$, was, also both anti-bacterial medicine showed satisfactory sensitivity.

After that, washing out the intra-mediastinal space with normal saline solution continuously performed for two weeks and 14 daily dose of intravenous vancomycin (VCM) therapy were given. Trough serum level of VCM measured on three occasions during his effective treatment ranged from 10.1 to 15.3 $\mu\text{g}/\text{ml}$. However, he remained febrile clinically ($>38^\circ\text{C}$) and white blood cell count and C-reactive protein again rose (Figure 2). The antibiotic regimen was changed to intravenous linezolid (10 mg/kg/day) 8 hourly. Two weeks after initiation of linezolid treatment, his blood culture was sterile and transthoracic echocardiography (TTE) and CT showed complete disappearance of abscesses. It is known well that the number of blood platelets decreases during linezolid injection but, the blood platelet is no significantly change. At discharge, he became no febrile and the treatment course was completed uneventfully. During the follow up, no other infectious episode was observed and he had been in remission for 2 years.

Discussion

Until recently, there were few therapeutic options for the treatment of MRSA infections, intravenous vancomycin remains the standard therapy, but usefulness of vancomycin may limit in the future.¹⁾ Pediatric MRSA endocarditis has a high mortality and relapse rate when treated with antibi-

otics alone. Failure of vancomycin to cure the infection in these patients could be attributed not only to the presence of a non-susceptible bacterial subpopulation but also to the presence of a prosthetic device. Linezolid has significant activity against Gram-positive species and a unique mechanism of action, and it lacks cross-resistance with other antimicrobials classed.²⁾ Linezolid inhibits initiation of protein synthesis by binding to the 50S ribosomal subunit at a different site than that used by chloramphenicol or clindamycin. Linezolid is a drug with well-recognized activity against MRSA and it could be a good therapeutic choice when glycopeptide treatment is not feasible.

In a few previous cases, there were successful treatments of MRSA endocarditis with linezolid.³⁾ To the best of our knowledge, however, none of pediatric patients were reported in the literature on the treatment of MRSA endocarditis with linezolid. Linezolid was well tolerated and safe in the treatment of MRSA bacteremia because clinical, microbiological, and survival outcomes are not inferior to those of vancomycin and adverse drug-drug or drug-food interactions.⁴⁾ The analyses of adverse events, clinical laboratory assays and other safety data suggest that linezolid was well tolerated compared with vancomycin.⁵⁾ This is only the first report in the literature on the treatment of pediatric MRSA endocarditis with linezolid. We had better to select for pediatric patient with the emergence of resistance to vancomycin in MRSA infections.

In conclusion, we have encountered a clinical impression of pediatric MRSA endocarditis resistant to vancomycin. We suggest linezolid could be an effective drug for the treatment of severe infections due to MRSA even in infant case.

References

- 1) STEVENS, D. L.; D. HERR, H. LAMPİRIS, *et al.*: Linezolid versus the treatment of methicillin-resistant *Staphylococcus aureus* infections. *Clin. Infect. Dis.* 34: 1481~1490, 2002
- 2) RUBINSTEN, E.; S. K. CAMMARATA, T. H. OLIPHANT, *et al.* and the Linezolid Nosocomial Pneumonia Study Group: Linezolid (PNU-100766) versus vancomycin in the treatment of hospital patients with nosocomial pneumonia: a randomized, double-blind, multicenter study. *Clin. Infect. Dis.* 32: 402~412, 2001
- 3) BASSETTI, M.; A. D. BIAGIO, V. D. BONO, *et al.*: Successful treatment of methicillin-resistant *Staphylococcus aureus* endocarditis with linezolid. *Int. J. Antimicrob. Agents* 24: 83~84, 2004
- 4) SHORR, A. F.; M. J. KUNKEL & M. KOLLEF: Linezolid versus vancomycin for *Staphylococcus aureus* bacteremia: pooled analysis of randomized studies. *J. Antimicrob. Chemother.* 56: 923~929, 2005
- 5) TSIODRAS, S.; H. S. GOLD, G. SAKOULAS, *et al.*: Linezolid resistance in a clinical isolate of *Staphylococcus aureus*. *Lancet* 358: 207~208, 2001